

GUM TISSUE REGENERATION IN PARONDONTITIS CORRECTION BY ALLOPLANT BIOMATERIAL

Aristova A.I., Musina L.A., Bulgakova A.I. Gizatullina E.R.

State institution - Russian Eye and Plastic Surgery Centre of the Russian Public Health
Ministry.

Ufa city.

Abstract

Along with the use of a complex histological, electronic microscopic, and immunohistochemical methods the question of morphofunctional condition of gum tissue was studied in the course of pathology and treatment by means of the dispersive Alloplant biomaterial (DAB). We investigated gum tissues before treatment and 3, 7, 14 days, 1, 6, 10, 12 months after DAB injection. The gum mucous membrane examination revealed features of chronic inflammation with cellular and fiber elements destruction. From the immunohistochemical point of view (PCNA) it was defined that after DAB was injected the epithelium regeneration went on due to the basal layer cells division and differentiation, that is it went on physiologically. In the connective tissue of its own plate collagenous fibers and blood vessel architectonics were being restored and the expression of transforming growth factor (TGF- β) was taking place. The epithelium structure of the test group patients (ascorbic acid injection) did not restore, meanwhile there was fibrosis with the dense scar formation on a plate of gingival mucous membrane.

Key words: parodontitis, Alloplant biomaterial, chronic inflammation, regeneration.

Parodontitis is a chronic tissue disease, when some destructive changes take place in epithelium and gum plate. Microorganism toxins and exchange products cause epithelium damage, the latter reduces the function of the resisting barrier [1, 2]. Morphologically this is revealed in oedema and epithelium desquamation. Further there develops an inflammatory reaction as well as in the connective tissue that is characterized by lymphohistiocytarios infiltration with the presence of plasmatic cells [1, 3, 4, 5, 6, 7]. The action of gram-negative microflora ferments plays a big role in the process of parodontium tissue destruction. They are hyaluronidaze, chondroitinsulfatase, protease, glucuronidase, collagenase. As a reaction to the microbiotic invasion polymorphonucleous leucocytes granules give rise to the active antibacterial substances, that destruct not only infectious agents but also intercellular matrix of gum tissue [8]. Depolymerization of the connective tissue proteins and their re-synthesis damage arise under the influence of these ferments [8].

By this time researchers detected the autoimmune component in parodontitis pathogenesis [9], that means pathology proceeds according to the model of delayed hypersensitivity.

One of the pathogenetic links in the disease progress is also hemodynamic disorders: vessels dilatation, their gradual permeability, deteriorating gum tissue trophism [11].

As the result of all mentioned above phenomena the disease becomes chronic with sclerosal nidus disorder. In the capacity of compensatory reaction and manifestation of the proliferative stage of inflammation one can point out irregular synthesis of collagen by fibroblasts [12]. As is well known, macrophages play an important role in collagenogenesis regulation [13]. That is why, as a rule, either reduction of number of histiocytes or their phenotipical immaturity is revealed in the course of connective tissue fibrosis [12]. As the result of destructive changes and the subsequent fibrosis there is damage in the tooth-gum connection that results in tooth elimination [1, 14].

In spite of the big number of existing methods of local anti-inflammatory therapy, they are not always effective and characterized of short duration [15]. Finally instead of the injured tissue restoration in most cases this process ends in its own plate fibrosis with damage of mechanic characteristics [15]. That is why the problem of parodontitis treatment, that is full regeneration of a gum, remains one of the most urgent tasks in stomatology.

According to the findings the dispersive Alloplant biomaterial (DAB) is an effective tissue regeneration stimulator, worked out in the Russian Eye and Plastic Surgery Centre. DAB represents a product of connective tissue fine-cut and processed in advance and contains collagen, proteglycans and glycoproteins [18]. It is shown that in the place of DAB injection one can observe monocytes accumulate and their ripe into full active macrophages which resorb the

biomaterial particles [17]. While the biomaterial is substituted by the newly-formed tissue a new fully active regenerate is formed [16, 19, 20, 21].

That is why the purpose of our research is to study morphological changes in gum tissue in case of parodontitis and after the Alloplant biomaterial injection.

Materials and methods of research

We have analyzed 89 tissue samples of soft gum tissues taken from males and females of within 13-60 years old. Out of 89 patients 52 had different degrees of parodontitis, 7 patients had a complex treatment with ascorbic acid (test group) and 30 patients were treated by the Alloplant biomaterial. Tissue samples were taken several times (in 3, 7, 14 days, 1, 6, 10, 12 months) in the area of interdental papilla and gum margin. The dispersive Alloplant biomaterial that we have used is made of connective tissue formations as per the special technology and is license-manufactured according to the USSR Health Ministry order № 87901-87 22.07.1987. DAB was injected once in the area of muco-gingival fold.

For histological investigation bioptic fragments were fixed in neutral 10% formalin and after dehydration they were placed in paraffin according to the accepted common method. The sections were stained with hematoxylin and eosin as per Van-Gieson, Mallory and Foot.

To make an electronmicroscopic examination biopsy tissues were fixed in 2,5% glutaraldehyde, prepared on cacodylate buffer (pH 7,2-7,4) to the final fixation in 1% OsO₄ solution. The material was dehydrated in solutions of growing spirit concentration and placed in epon-812 according to the common accepted method [22]. Half-thin and ultra-thin sections were prepared on ultratome-LKB-III 8800 (Sweden). Ultra-thin sections were contrasted by uranyl acetate 2% hydro solution, lead citrate as per Raynolds [22] and were examined using a transmissible Jeol-100XB 8000-13000 power microscope.

The immunohistochemical studies were made on paraffin sections by means of monoclonal anti-bodies to transforming growth factor TGF- β , to its receptors TGF β -RI, and also to the nuclear antigen of proliferative cell PCNA (Santa Cruz Biotechnology, Inc., the USA).

The cells got counted on histological preparations at magnification X60 in 20 visual fields at the rate of 100 cells. Reliability was defined according to Student's criterion ($p < 0,05$) [23]. The diagram was made in Microsoft Excel.

Research findings

The findings of our histological research revealed more or less developed chronic inflammatory process in the gums of parodontitis patients. At a mild form of the disease one can observe an increased desquamation of the horny layer cells. Edema of cells and components of

intercellular matrix was revealed (Fig.1). In the basis of the connective tissue arose features of the collagen fiber destruction in the form of mucoid swelling and slightly expressed picrinophilia when Van-Giezon stained. In the dermic papillary layer one could see dilated capillaries with erythrocytes stasis symptoms.

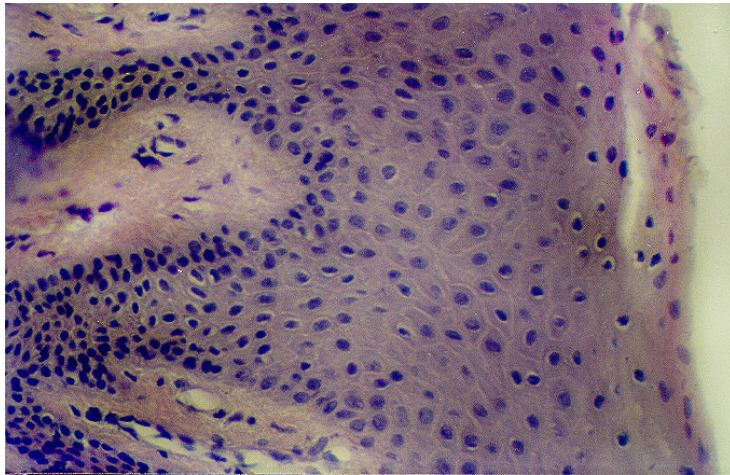


Fig. 1. Mild form of parodontitis. Acanthosis, edema and increase of horny cellular layer desquamation. Magnified x 100. Stained with hematoxilin and eosin.

At an average and severe forms of the disease pathomorphological picture got even worse by the presence of polymorphonuclear leucocytes and immunocompetent cells in the gum stroma. The average stage of the disease was characterized by the prevalence of lymphomacrophagal infiltration with the presence of segmentonuclear leucocytes and the severe form was characterized mainly by the lymphoplasmacytic infiltration (Fig. 2).

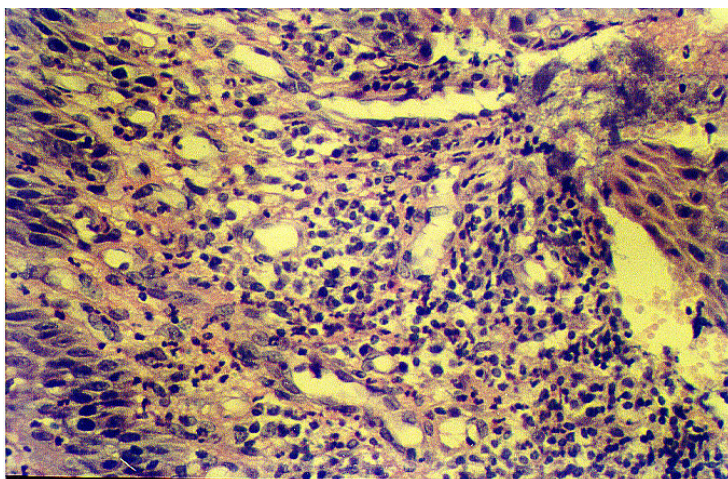


Fig. 2. Grave form of parodontitis. Plasmacyte and lymph-macrophage infiltration of a stroma. Hemorrhagic saturation. Magnified x 60. Stained with hematoxilin and eosin.

There were changes of fibrillar structure and common architectonics in collagenous fibers. At a grave form of the disease there were revealed collagenous fibers fragmentation and most part of the stroma homogenization on the electro-microscopic level, disappearance of cross-

cut lines of the preserved fibrils (Fig.3.). On the other hand when staining the preparations as per Mallory there appeared newly-formed collagenous fibers with chaotic architectonics.




Fig.3. Grave form of parodontitis. Collagenous fibers destruction. Magnified x 8000. Electronic microphotography.

An intensive hemorrhagic saturation was detected in its plate. In capillaries there was hyperemia and erythrocytes sludge. At the grave form of the disease one could observe signs of the capillary network reduction with the complete obliteration of the capillaries lumen.

Immunohistochemically TGF- β expression was revealed in the connective tissue and this expression correlated with a parodontitis stage (Fig.4). It is worth mentioning that at the grave stage this cytokine was detected both intracellularly and in the extracellular matrix (Fig. 5).

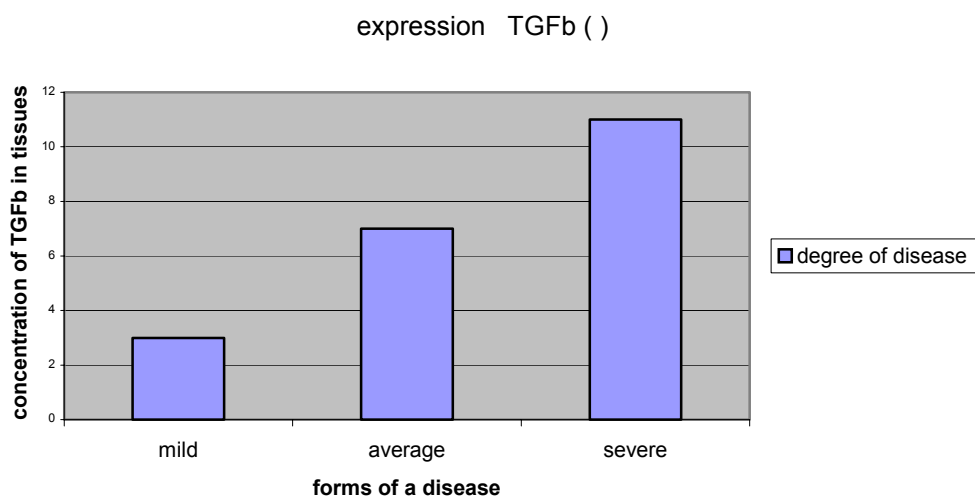


Fig.4. TGF- β expression depending on the form of parodontitis

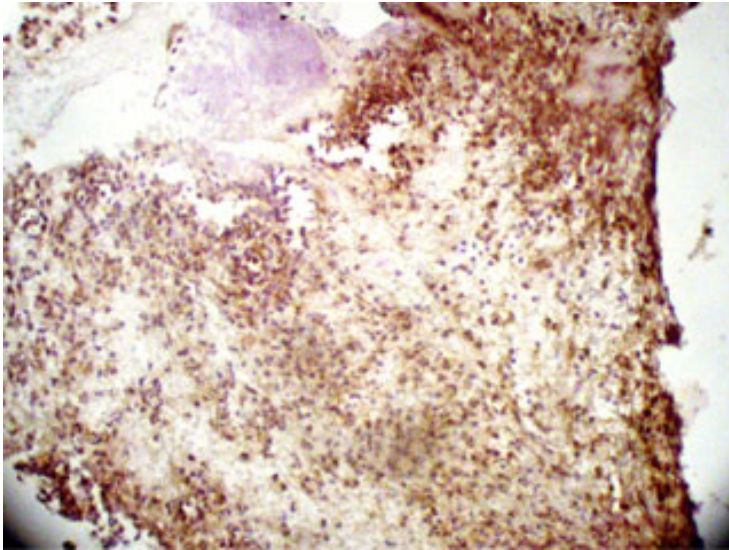


Fig. 5. Grave form of parodontitis. Pronounced TGF- β expression in a gum stroma. Magnified x 60. Stained up with hematoxylin.

At the grave form of parodontitis pathologic changes reached their maximum level in epithelium. Together with the increase of horny cellular layer desquamation micro- and ultra-structure of basal and thorny layer epitheliocytes altered: there appeared vacuoles of perinuclear spaces, the number of organelles reduced in cellular cytoplasm, plenty of vacuoles and pinocytous bubbles got defined while tono- and microfilaments were nearly unseen. Ocantolitic bubbles, small-grained material and remnants of the destroyed connective bridges were found in enlarged intercellular spaces (Fig. 6).

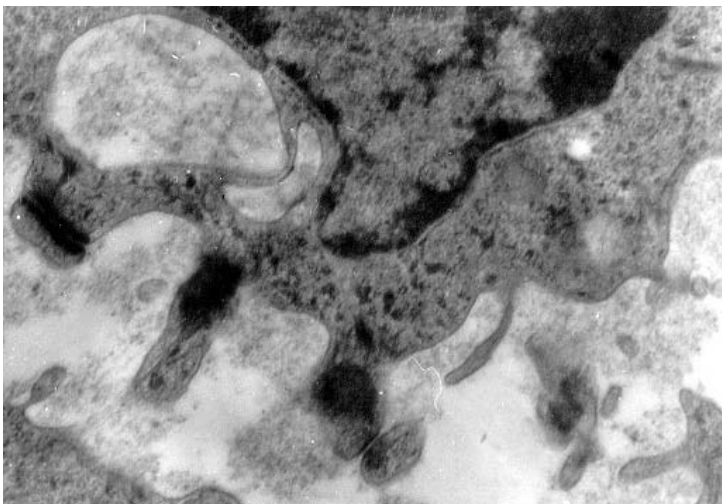


Fig. 6. Average stage of parodontitis. Cytoplasm vacuolization and destruction of epitheliocytes desmosomes. Magnified x 13000. Electronic microphotography.

When there was an immunohistochemical research (PCNA) proliferous epitheliocytes were found not only in a basal layer, but also in a thorny one (Fig. 7).

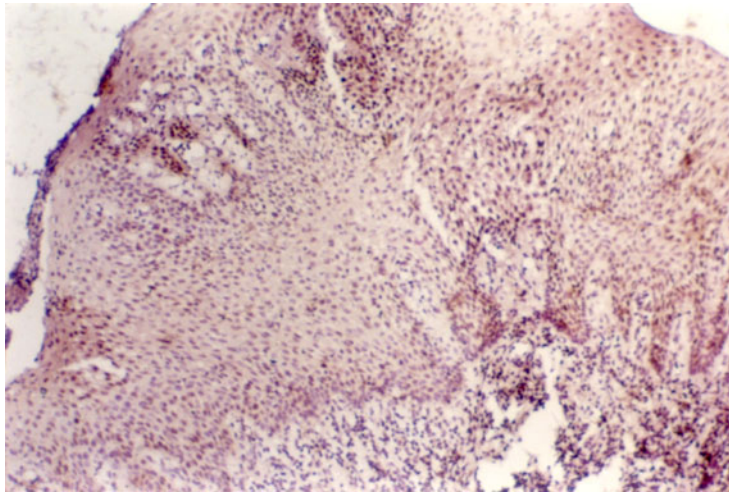


Fig. 7. Grave stage of parodontitis. PCNA expression in cells of basal and thorny layer of epithelium. Magnified x 60. Stained up with hematoxylin.

There were certain morphofunctional positive changes 7 days after DABM was injected in a gum tissue. One could see reduction of cellular and intercellular edema in multi-layer flat epithelium. Horny cellular layer desquamation was considerably reduced or completely disappeared. Electronic-microscopic examination showed that the number of tonofilaments bundles found in thorny and granular layers of epithelium cells increased. Keratogelin granules were detected intracellularly and extracellularly. (Fig.8.)

Cellular cytoplasm of basal layer contained plenty of free ribosomes, a developed network of granular endoplasmatic reticulum, Goldgi's complex.

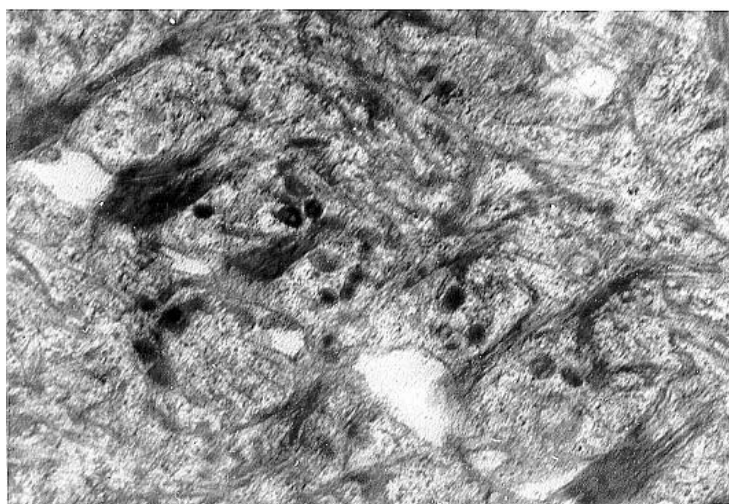


Fig. 8. Average stage of parodontitis 7 days after DAB was injected. Tono- and microfilaments, keratogelin in epithelium. Magnified x 10000. Electronic microphotography.

Immunohistochemical examination showed that PCNA reveals itself in epithelium only in basal cellular layer (Fig.9). The number of mitotic cells was considerably reduced in comparison with gum epithelium before DAB was injected (Fig. 10).

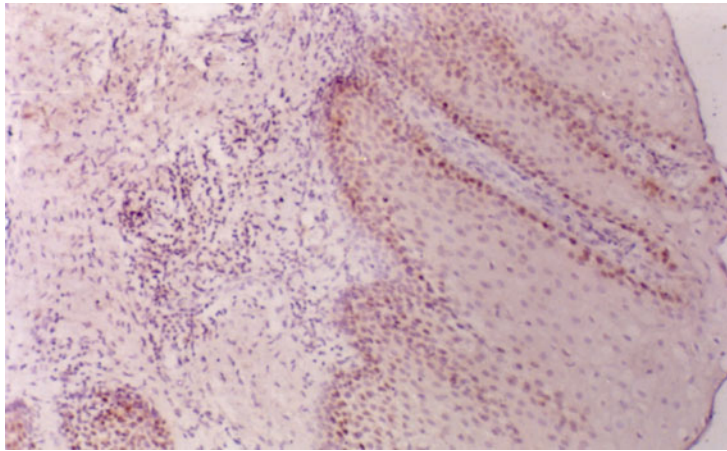


Fig. 9. PCNA expression in basal cellular layer 14 days after DAB was injected in gums of the average form of parodontitis. Magnified x 60. Stained up with hematoxylin.

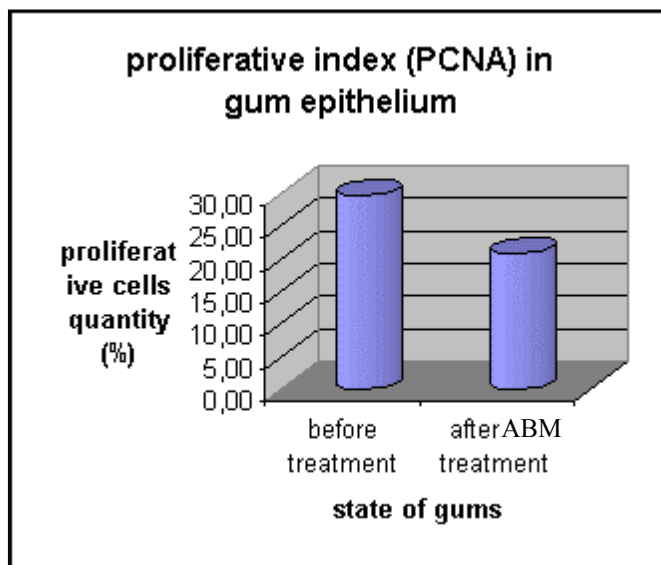


Fig. 10. Proliferative index (PCNA) in epithelium layer.

The level of the inflammatory infiltration reduced and gradually was replaced by macrophage-fibroblast one in the connective-tissue gum basis. The electromicroscopic examination showed that these cells actively contact each other and that a lot of immature macrophages and histiocytes migrate and phagocyte the injured detritus.

In the papillary layer there appeared newly-formed blood vessels with spindle-shaped endothelial cells the ultra-structure of which clearly pointed at the fact that secretory activity got increased and trans-endothelial exchange got intensified. At the borders of the cytoplasmic membrane there appeared a great number of pinocytous bubbles. Endothelicytes plasmalemma

formed villi pointed at the lumen of a vessel and this enlarged the area where the cells and liquid medium come into contact with each other.

30 days after DAB was injected, the architectonics and multi-layer flat epithelium structure became completely restored. The connective-tissue basis had no expressed inflammatory infiltration nidi. The cellular structure contained mainly fibroblastic cells: fibroblasts and fibroclusts. The connective gum tissue became vascularized to the maximum (Fig.11).

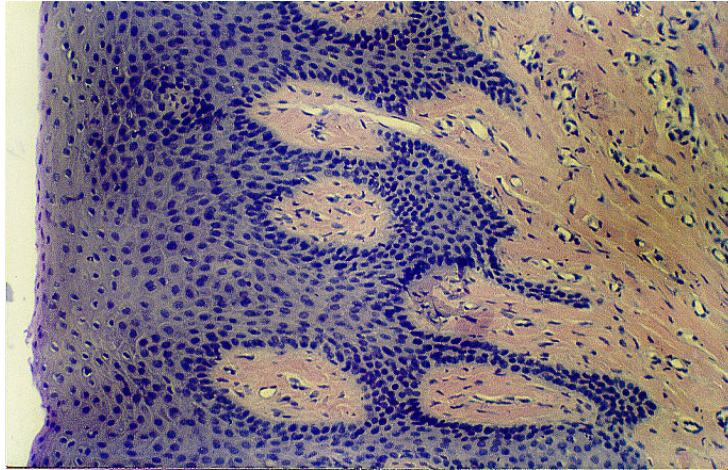


Fig. 11. Middle stage of parodontitis 30 days after the Alloplant biomaterial was injected. Inflammatory infiltration liquidation, newly-formed blood vessels appearance. Magnified x 60. Stained with hematoxylin and eosin.

Thin reticulinous fibers were found in the papillary layer (collagen of the III type), and revealed themselves while the preparations were silvered according to the Foot's method (Fig. 12).

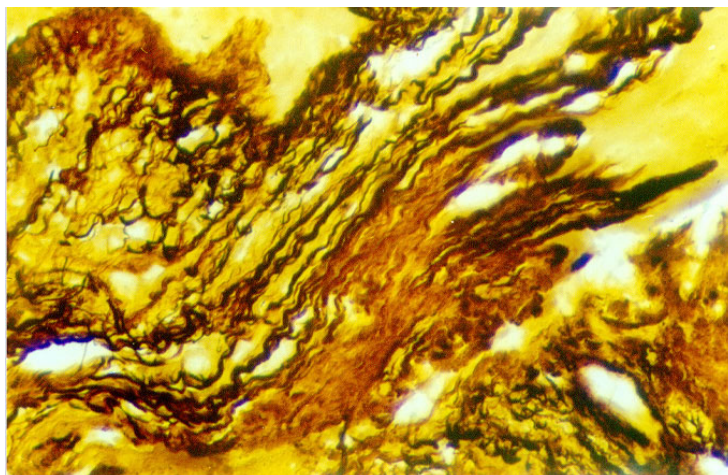


Fig.12. Reticulinous fibers in gum connective tissue 40 days after biomaterial injection in case of the grave form of parodontitis. Magnified x 60. Impregnation according to the Foot's method.

In deeper stroma layers one could detect fuxinifillary bundles of collagenous fibers that were tightly packed and placed at an angle to each other (Fig.13).

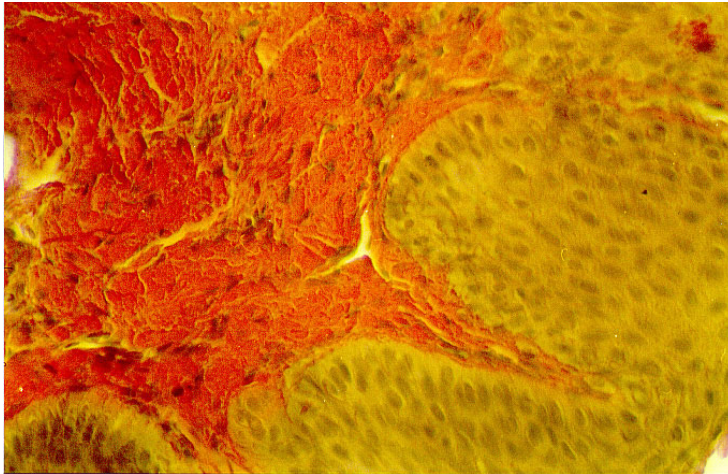


Fig.13. Connective-tissue gum basis is restored 40 days after the biomaterial injection. Before treatment – average stage of parodontitis. Magnified x 60. Van-Gieson stained.

TGF- β expression in its plate to gum mucous membrane considerably reduced within a short time period. (7 days), and already a month later this factor was not revealed (Fig. 14).

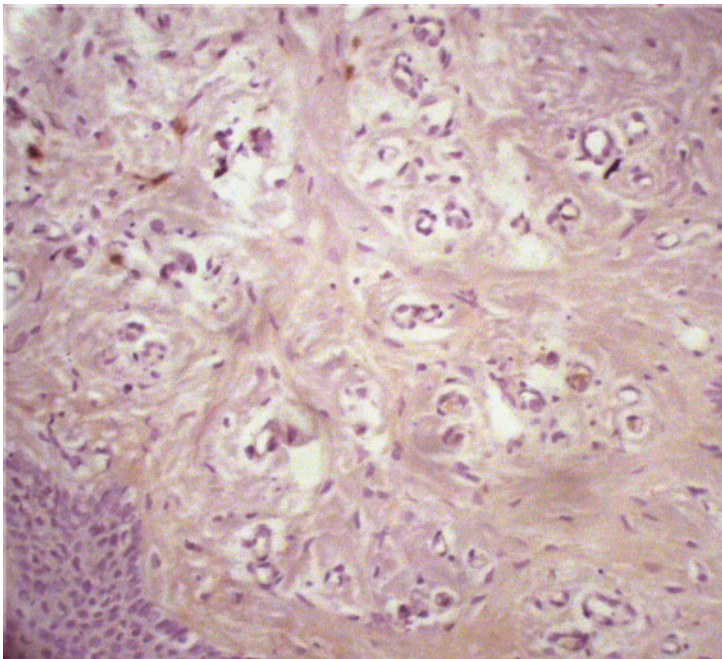


Fig. 14. Considerable reduction of TGF- β expression in stroma cells 14 days after the biomaterial injection. Before treatment – grave form of parodontitis. Magnified x 60. Stained up with hematoxylin.

Acanthosis, signs of hydropic epitheliocytes dystrophy and cellular desquamation of the horny layer remained in tissue samples, taken from a test-group patients ranging from 7 days to a

year (treatment with the use of ascorbic acid). The connective-tissue basis represented a dense avascular cicatricial tissue with the disordered collagen fibers architectonics (Fig.15).

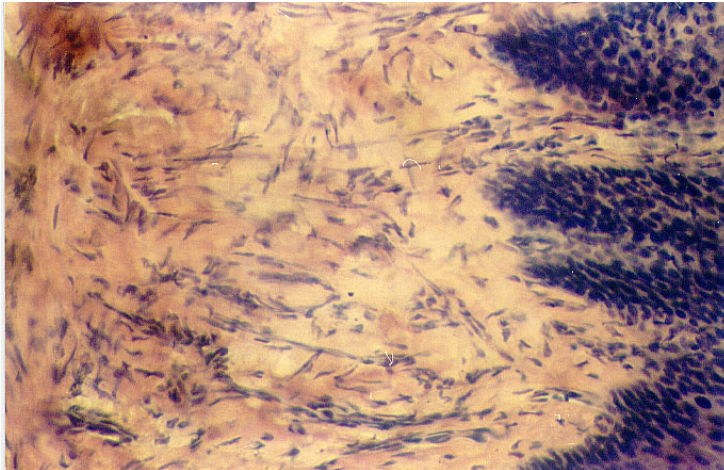


Fig. 15. Average stage of parodontitis 2 months after treatment based on ascorbic acid. Stromal elements disorganization. Magnified x 50. Stained with hematoxylin and eosin.

Discussion.

The given above research showed that in parodontitis all gingival layers are pathologically injured and this fact correlates with the results of other investigations [8, 15].

At the average form of the disease morphological changes are represented by desquamation and acanthosis and chiefly take place in the epithelium. It is well known that acanthosis (epithelium enlargement) is caused by the disorder in the basal membrane integration [24]. We have defined its swelling and the subsequent lysis. When revealing the epithelium cells expressing PCNA we noted that not only the basal layer cells proliferation but also that of the thorny one caused epithelium enlargement. One may suppose that epithelium dilatation is a compensatory reaction to destructive changes but this doesn't restore the normal architectonics of epithelium layer.

Inflammatory changes arise as well in the proper gum plate as a result of the epithelium damage which is in its turn a protective barrier. The most primary changes take place in vessels of a microcirculatory channel. We found cases of erythrocytes stasis, micro-thromboses in capillary lumens and also endotheliocytes and basal membrane destruction proved the presence of vascular damages. Along with the disease progression such phenomena as hyalinosis and vascular wall sclerosis and capillary network reduction took place. The signs described above allow us to judge about the pronounced trophic disorders which make an inflammatory process go aggravated.

While the pathology developed one could as well watch definite dynamics in the structure of the cellular infiltrate in a proper gum plate: polymorphonuclear leucocytes – macrophages – lymphocytes – plasmacytes. The given findings point at the immune nature of the gum tissue inflammation. It is known that microbiotic hyaluronidase makes connective tissue more transparent due to the glycosaminoglycans destruction and tissular damage leads to the antigen structure disorder accompanied by auto-antigens [6, 25, 26]. K Takahashi and co-authors (2001) also point at the auto-immune mechanism of parodontium damage on the basis of the revealed massive lymphomacrophagal infiltration and expressed cellular cytolysis [27].

As is known TGF- β is expressed in case of a damage by the connective tissue cells. The release of the cytokine allows to attract neutrophils, macrophages/monocytes, fibroblasts and induces fibrillogenesis [28]. Some authors [29, 30, 31] discovered TGF- β increased expression which correlates with fibrosis development. The dynamics of TGF- β expression that we defined testifies to the fibrotic enlargement in a proper plate thus a grave form of the disease.

So according to our findings in parodontitis gum tissue regeneration ends in cicatricial tissue formation.

After DAB gets injected in the gum tissue which is pathologically changed, the nature of infiltration gradually changes: neutrophils and lymphocytes disappear, active macrophages and fibroblasts start prevailing. Together with secretory macrophages we discovered both collagenoblasts and fibroblasts in the stroma. Soon after DAB injection (3-10 days) the signs of active fibrillogenesis appeared. Then 2-4- weeks later collagenous fibrils were strictly lined and had a clear cross-section. The formed collagenous fiber bundles were variously orientated and had tinctorial features pointing at their maturity (fuchsinophilia).

Reduction of TGF- β expression in the parodontium tissue proved that normal fiber architectonics was restored and cicatricial changes disappeared. The given facts show that the products of the biomaterial resorption promote to keep up the balance between the process of synthesis and extra-cellular matrix degradation. It is supposed that the products of DAB degradation are the factors that promote fully active maturity and macrophages activation [17]. Secretory macrophages play a special role in the process of regeneration. They form microsurrundings with the help of short- and long-distant cytokines and regulate cellular differentiation, that of fibroblasts as well. [32, 33].

Together with regulated fibrillogenesis we discovered signs of vascular channel regeneration that proves an improvement of trophics and metabolism in parodontium tissues. It is known that DAB implantation causes full micro-vascular regeneration [20, 21]. One could judge about it through the disappearance of signs of hydropic, albuminous, and adipose cellular dystrophy. It is known that except growth factors, factors of fibroblastic migration and that of

collagenous secretion, macrophages secrete factors of angiogenesis [33]. Moreover, microvessels can grow and fibroblasts can proliferate synchronously influencing each other [34, 35, 36].

Improvement of the connective tissue trophics and regulation of its structure seem to provide regeneration of basal membrane and epithelium. The cardinal difference between pathological enlargement of epithelium and its regeneration after DAB injection is that regeneration takes place only owing to the proliferation of basal layer epitheliocytes. That means one can speak about the restoration of physiological nature of epithelium regeneration which is characterized by the proliferative activity of the particularly basal layer cells [37, 38]. One could judge about the successful regeneration of epithelium also due to the fact that inter-epithelium bridges restored, inter-cellular spaces narrowed and there appeared granules of keratohyaline in cellular cytoplasm. It is known that keragialin granules are connected with bundles of tonophilaments and the latter form complexes with desmosomes which contain plenty of glycosaminoglycans [30]. One may suppose that glycosaminoglycans that left DAB take part in the synthesis of keratogialin.

Thus, the use of the dispersive Alloplant biomaterial provides full regeneration and restoration of microcirculation and exchange processes in case of treatment of different forms of parodontitis.

References.

1. Ivanov V.C. Cases of parodontium. –M.: Medicine, 1989. - 272 p.
2. Danilevski N.F. Guidance to practical classes of therapeutic stomatology. Kiev, 1990. – 135 p.
3. Svrakov D, Atanasova Y. Parodontopathies (etiology, clinic and treatment).- Sophia.: Medicine and physical training, 1962. – 212p.
4. Dominic K. Parodontopathies. Warsaw.: POLISH STATE MEDICAL EDITION, 1967. -379 p.
5. Nikitina T.V. Parodontitis. – M.: Medicine, 1982. – 256 p.
6. Krekshina V.Y. Parodontitis. – M.: Medicine, 1983. – 160 p.
7. Bezrukova A.P. Parodontics. M.: ZAO “Stomatological scientific centre”, 1999. - 333 p.
8. Straka M. Parodontics – 2000. Etiopathogenesis of parodontal diseases.// Innovations in stomatology.- №8. – 2001. – p. 9-18.
9. Barabanova L.V. , Tsepov L.M., Meshkova R.Y. Immune damages in inflammatory cases of parodontium (review of scientific works) // Innovations in stomatology. - №4. – 2002. –p. 23-26.
10. Royt A., Brostoff G., Meil D. Immunology. – M.: Mir, 2000.- p. 464-489.
11. Tarasenko L.M. Pathogenesis of injured parodontium in case of stress: Abstract of doctoral dissertation. – M., 1985.- 41p.
12. Serov V.V., Paukov V.S. Inflammation. Guidance to physicians. – M.: Medicine, 1995. – 640 p.
13. Serov V.V. Shehter A.B. Connective tissue. – M.: Medicine, 1981. – 312 p.
14. Grudyanov A.I. Methods of prophylaxis of parodontium cases and their grounds. //Stomatology. – 1995. Vol. 74, №3. – p. 21-24.
15. Perova M.D. Biological mechanisms of reparative parodontium tissue regeneration // Innovations in stomatology. - №8. -2001. –p. 62-69.
16. Muldashev E.R. Theoretical and applied aspects of “Alloplant” allografts production in facial surgery: Abstracts of doctoral dissertation. Saint-P-g, 1994.- 40 p.
17. Muslimov S.A. Morphological aspects of regenerative surgery. – Ufa.: Bashkortostan, 2000. – 168 p.
18. Hasanov R.C. Injective form of “Alloplant” allografts: production, analysis and biological activity: Abstract of doctoral dissertation. – Perm, 1999. – 24 p.

19. Muldashev E.R., Gabbasov A.G., Nigmatullin R.T. and others. Some ways of new allografts selection for ophthalmosurgery // Topical questions of organic and tissular grafting. / H.I. Pirogov 2-nd MOLGMI. – Moscow, 1978. – Vol. 113. – Edit. 23. – p. 21-22.
20. Muslimov S.A. Micro-circular normal channel of bulbar conjunctiva and that of experimental alloplasty. Abstracts of thesis for a master's degree. – Yaroslav, 1984. – 20 p.
21. Nigmatullin R.T. Morphological aspects of connective-tissue allografting: Abstracts of doctoral dissertation. – Novosibirsk, 1996. – 40 p.
22. Wickly B. Electronic microscopy for beginners. Translated from English. –M.: Mir.- 1975. – 324 p.
23. Strelkov R.B. Express-method of statistic processing of experimental and statistic findings. – M.: N.I. Pirogov 2-nd MOLGMI, 1986. – 86 p.
24. Kiselyova A.F., Chizhevski I.V. (1969). In the book by T.V. Nikitina. Parodontitis.- M.: Medicine, 1982.- p. 20-21.
25. Peter R. Microbiologie des parodontalyses //Rev. Frans. Odonto-Stomat.- 1970. – Vol.17. – p. 1041 – 1062.
26. Jackson D. (1976) In the book by Nikitina T.V. Parodontitis. – M.: Medicine, 1982. – p. 6-7.
27. Takahashi K., Ohyama H., Kitanaka M. et al. Heterogeneity of host immunological risk factors in patients with aggressive periodontitis // J. Periodontol. – 2001. – Vol. 72, №4. – p. 425-437.
28. Cordeiro M.F., Gay J.A., Khaw P.T. Human anti-transforming growth factor-beta2 antibody: a new glaucoma anti-scarring agent // Invest Ophthalmol Vis Sci. – 1999.- Vol. 40, №10.- P. 2225-2234.
29. LeRoy E.C., Trojanowska M.I., Smith E.A. Cytokines and human fibrosis // Eur Cytokine Netw.- 1990. – Vol. 1, №4. – p. 215-219.
30. Miyazno K., Heldin C.H. The mechanism of action of transforming growth factor-beta // Gastroenterol Jpn. – 1993. – Vol. 28. – Suppl 4.- p. 81-85.
31. Rodemann H.P., Binder A., Burger A. et al. The underlying cellular mechanism of fibrosis // Kidney Int Suppl. – 1996. – Vol. 54.- p. 32-36.
32. Carr J. Macrophages. – M.: Medicine, 1978. – 187p.
33. Mayanski D.N. Kupfer cells and the system of mono-nuclear phagocytes. – Novosibirsk: Nauka, 1981. – 255p.
34. Lobb R., Sasse J., Silvian R. Purification and characterization of endothelial cell growth factors // j.Biol. Chem.- 1986.- Vol.261.- p. 1924-1928.

35. Heimark R.L., Twardzik D.R., Schwartz S.M. Inhibition of endothelial regeneration by type-beta transforming growth factor from platelets // Science.- 1996. – Vol.233.- p.1078-1080.
36. Schweigerer K., Neufeld G., Gospadoriwicz D. Capillary endothelial cells express basic fibroblast growth factor //Nature. – 1987.- Vol. 325. – p. 257 – 259.
37. Ulumbekov E.G. Chelyshev U.A. histology (introduction to the pathology). – M.: GEOTAR MEDICINE, 1998.- 960p.
38. Bykov V.L. Cytology and common histology (functional cellular and human tissular morphology)-Saint. P-g.:SOTIS, 1999. – 520p.
39. Akimov V.G., Albanov V.I., Bogatyryova I.I. et al. // Dermal pathology /Edited by V.N. Mordovtseva, G.M. Tsvetkova. – M.: Medicine, 1993.- 336 p.